



# Excavation | PolyBur



Patent: DE 10 2008 010 049 - EP 2 260 787

## Excavation in the vicinity of the pulp.

In close collaboration with Prof. Dr. Kunzelmann of the Ludwig-Maximilians University of Munich, we have developed a round bur made of polymer. This bur is based on the concept of a self-limiting caries treatment developed by Dr. Daniel Bosten of the Temple University, USA .

In order to guarantee conservative excavations preserving as much hard dental substance as possible, a clinical difference between to layers of dentin had to be made up to now: an outer, infected layer of dentin (which cannot be remineralised and has to be removed) and a carious inner dentin layer (which can be remineralised and should be preserved). We know now that there is no a clearly defined border between the two layers, but a diffusion process is taking place forming a gradient – away from the carious lesion towards unchanged dentin with increasing mineralisation and hardness.

Within this gradient, the dentist has to correctly identify the end of the bacterial colonisation – a difficult task! This is where the PolyBur P1 comes into its own: It is capable of determining the correct extent of the excavation all by itself!

What does that actually mean? The material hardness of the PolyBur does not allow an

excessive preparation. Once all soft, carious dentin has been removed, the instrument automatically blunts on hard, healthy dentin – in other words, it limits itself.

Attention: The PolyBur is used in addition to conventional instruments whenever excavation is to take place in the vicinity of the pulp.

The peripheral parts of the cavity are first treated with standard round burs (for example with the CeraBur K1SM which – although it allows tactile work – is a lot harder than the P1). This is followed by the PolyBur which is ideally suited for minimally invasive excavation near the pulp thanks to its self-limiting properties.

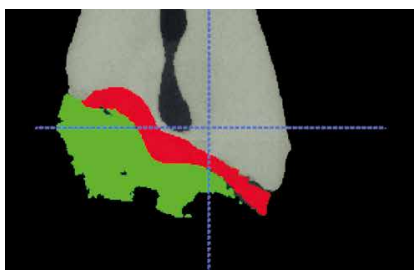
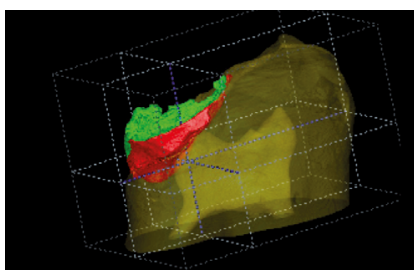
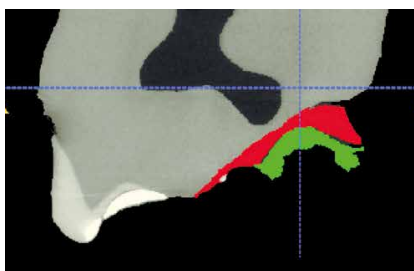
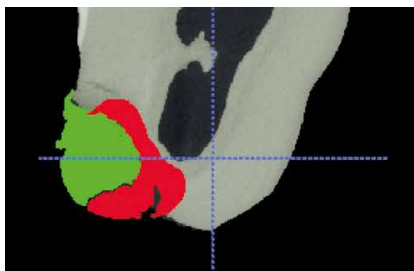
The PolyBur helps to preserve the essential 0.5 to 0.7 mm of dentin in the vicinity of the pulp. These might make the crucial difference between a filling and an endodontic therapy. Avoiding the latter can be a decisive advantage to the patient.

If the pulp is opened during the treatment, this means that the damage is too advanced and this could not be avoided. The pulp was already affected and an endodontic therapy is required.

### Facts to be considered when evaluating the results.

After excavation with the PolyBur, the surface of the dentin is not as hard as the dentist has come to expect.

The normal control with a probe can therefore not be carried out. The dentin is not going to clink and the probe might leave scratch marks on the surface of the dentin. This is no cause for concern but part of the concept. Any dentin worth preserving has been preserved. The surface of the dentin is going to get back to normal within the next few months, in an ideal scenario, it should even remineralise.



### Analysis of the Micro CT

The image shows which areas are removed with a tungsten carbide bur (red) and with the PolyBur (green). The increased preservation of substance is evident.

### Note:

A decisive factor for the success of treatments to maintain the vitality of the tooth is a permanent, absolutely bacteria-proof restoration. This is of essential importance in selective caries removal because this cuts the supply of nutrients to the remaining bacteria, thereby preventing the residual carious lesion from spreading. Adhesive restorations meet these requirements, provided that they have been implemented correctly. (Bibliography reference no. 5)

### The control radiograph looks like the caries has recurred.

The reduced hardness is due to the partial demineralization of the dentin. Unfortunately, the partial demineralisation of the dentin also entails a reduced absorption of X-rays, which is why the finished filling might look on the radiograph as if the caries had recurred. This is a positive sign because it proves that the PolyBur actually works. The solution could be a dentin adhesive with an increased radiopacity. This is currently being researched.

The best option is to explain the situation to the patient. Every patient understands that by choosing this treatment, hard dental substance can be preserved and an unpleasant root canal treatment might even be avoided. If the marginal regions of an adhesive filling are tightly sealed, no unexpected problems should arise. This has been shown by classical studies (see references 1 - 4).

## Indication:

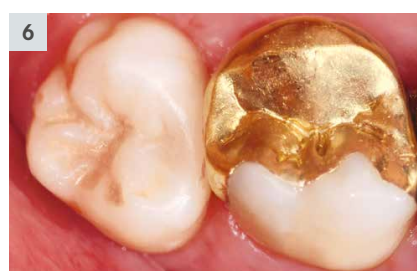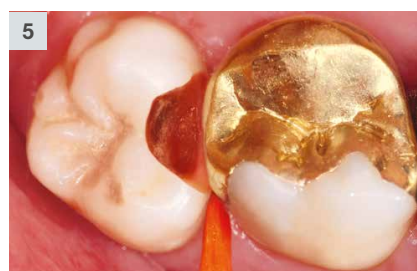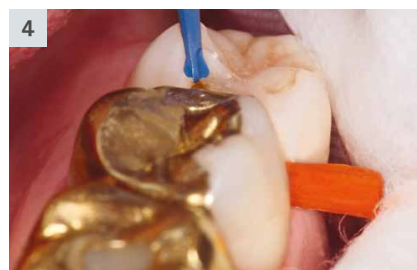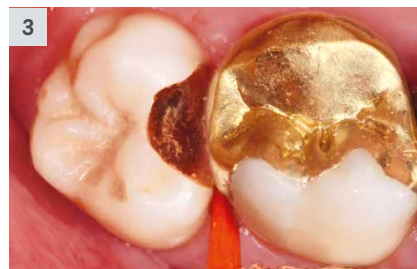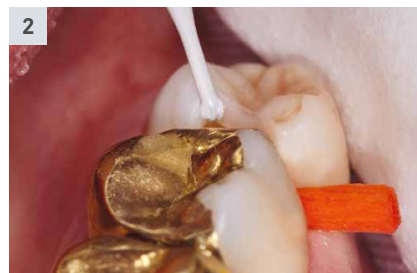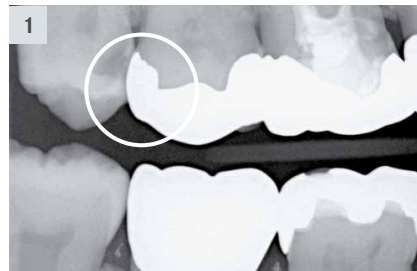The PolyBur is used for the excavation of soft carious lesions in the vicinity of the pulp of clinically symptom free milk and permanent teeth.

## Contra-indications:

- Caries that has already caused clinical symptoms
- Dark, discoloured dentin (e.g. Maillard reaction)
- Hard dentin that can be re-mineralised
- Caries along the dentino-enamel junction

## Clinical sequence:

1. Bitewing radiograph shows an incidental finding on the mesial side of tooth 18.
2. After opening the cavity with diamond instruments, peripheral portions of the carious lesion are excavated with the CeraBur K1SM.204.014.
3. Situation after the use of the CeraBur: the central portions of the cavity have not yet been (finally) treated.
4. Excavation near the pulp with the PolyBur P1.204.014.
5. The PolyBur has removed soft dentin; any dentin worth preserving has been preserved.
6. Finished composite filling The marginal areas of the cavity have been treated according to the classical criteria of the adhesive technique, in order to guarantee a tight seal of the cavity.



## Recommendations for use:

- The PolyBur is ready to use. It can be used straight after removal from the pack. The instrument has to be discarded after use (disposable instrument).
- The instrument is used at a speed of  $\approx_{opt.}$  2.000 – 8.000 rpm.
- Cooling with water spray is possible but not essential.
- The PolyBur cannot replace traditional round burs. It is used in addition to these burs, in the vicinity of the pulp.
- Remove soft defects first. Work outwards from the centre.
- Work with low pressure. The specifically determined elasticity of the instrument ensures that the PolyBur bends if too much pressure is applied. This special control function prevents the application of excessive contact pressure.
- The excavation is concluded as soon as the PolyBur stops removing further substance. The blades do not necessarily have to blunt, this only happens after prolonged work on hard material.
- With a little practice, one instrument per cavity should be enough.

#### Handy hint:

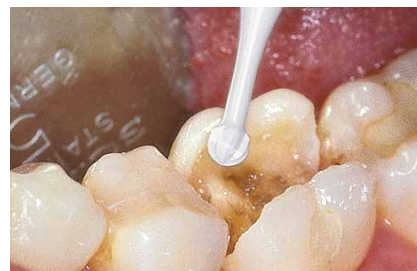
The efficiency of the PolyBur can be increased in combination with Carisolv. This is because Carisolv contains sodium hypochlorite, which causes denatured collagen to dissolve. It facilitates substance removal and disinfects the cavity.

## New CARISOLV® System

For further information and advice, please contact:  
www.carisolvsystem.com  
Rubicon Life Science International customer service under  
+46 31 780 68 20 or customer@rlsglobal.se

#### Scientific advice:

1. Mertz-Fairhurst EJ, Curtis JW, Ergle JW, Rueggeberg FA, Adair SM:  
*Ultraconservative and cariostatic sealed restorations.*  
J Am Dent Assoc 1998;129:55-66.
2. Mertz-Fairhurst EJ, Schuster GS, Fairhurst CW:  
*Arresting caries by sealants: Results of a clinical study.*  
J Am Dent Assoc 1986;112:194-198.
3. Mertz-Fairhurst EJ, Schuster GS, Williams JE, Fairhurst CW:  
*Clinical progress of sealed and unsealed caries.*  
*1. Depth changes and bacterial counts.*  
J Prosthet Dent 1979a;42:521-526.
4. Mertz-Fairhurst EJ, Schuster GS, Williams JE, Fairhurst CW:  
*Clinical progress of sealed and unsealed caries.*  
*11. Standardized radiographs and clinical observations.*  
J Prosthet Dent 1979b;42:633-637.
5. Scientific publication of the Deutsche Gesellschaft für Zahnerhaltung (DGZ):  
*Aktuelle Empfehlungen zur Kariesexkavation.*  
DZZ 72 (6) 2017.



#### Handy hint:

For the preceding excavation of peripheral parts, we recommend our ceramic round bur K1SM (product information leaflet 410453)



#### Set 4608.204

With 25 instruments  
(10 x 014 | 10 x 018 | 5 x 023)

Each PolyBur is individually wrapped and ready to use.



P1.204.014/018/023

#### Scientific advice:

Prof. Dr. Karl-Heinz Kunzelmann  
Poliklinik für Zahnerhaltung und Parodontologie  
Ludwig-Maximilians-Universität München